

Pituitary adenomas and craniopharyngiomas are CDX2 negative neoplasms

Jens Schittenhelm¹, Tsambika Psaras², Richard Meyermann¹, Jürgen Honegger², Rudi Beschorner¹

¹Institute for Brain Research, Eberhard-Karls-University, Tuebingen, Germany, ²Department of Neurosurgery, Eberhard-Karls-University, Tuebingen, Germany

Folia Neuropathologica 2010; 48 (2): 75-80

Abstract

Objectives: Previous studies have shown an inverse correlation between the expression of CDX2 (also known as CDX3) and tumour grade, stage and lymph node dissemination in colorectal adenomas and adenocarcinomas. Although less frequent, expression of CDX2 has also been reported in various other epithelial tissues and carcinomas. While many neoplasms have been studied, to date, no data is available on CDX2 expression in craniopharyngiomas. Furthermore, only very few data are available on CDX2 expression in normal pituitary gland tissue and/or pituitary adenomas.

Material and methods: We investigated CDX2 expression in 28 normal pituitary glands, 75 pituitary adenomas of varying hormonal activity (including 7 invasive adenomas and 7 atypical adenomas) and 23 craniopharyngiomas (17 adamantinous and 6 papillary) in tissue microarrays.

Results: None of the pituitary adenomas, craniopharyngiomas and normal pituitary glands showed expression of CDX2.

Conclusions: There is no evidence for that CDX2 might play a role in tumourigenesis, invasive growth or tumour recurrence of pituitary adenomas or in tumourigenesis of craniopharyngiomas. But, presence of CDX2 expression might be useful in distinguishing intrasellar metastases from primary tumours of the sellar region.

Key words: differential diagnosis, sellar tumours, brain metastasis.

Introduction

The evolutionary conserved caudal-related homeobox transcription factor CDX2 (previously called CDX3 in humans) is important in axial development and differentiation of the intestine. It modulates proliferation, apoptosis and cell-adhesion [9]. While absence of CDX2 gene in knock-out mice is lethal, heterozy-

gotic mice develop neoplastic changes in the colon suggesting that CDX2 plays a role as a tumour suppressor gene [5]. *In vitro* studies suggest that *Cdx2* gene expression is regulated through NF-kappaB, PI3K/PTEN and OCT1 signalling pathways [15,16]. In humans, CDX2 is constantly expressed in normal colorectal mucosa and, to a lesser extent, in several other tissues such as pancreas [22]. Loss of CDX2

Communicating author:

Rudi Beschorner, MD, Institute for Brain Research, Calwerstr. 3, 72076 Tuebingen, Germany, phone +49-(0)7071-2983318, fax +49-(0)7071-294846, e-mail: rudi.beschorner@med.uni-tuebingen.de

expression is associated with increasing tumour grade, tumour stage and lymph node metastasis in colorectal neoplasms [1]. However, there is a growing list of neoplasms that may also show an expression of CDX2 in neoplastic cells. These include ovarian [21], lung [21,23], endometrial [36], breast [23], thyroid [37] and prostate [11] cancer. Furthermore CDX2 has been implicated in lymphoma progression [10] and aberrant expression has been demonstrated in acute myeloid leukaemia [27] and acute lymphoblastic leukaemia [24,34]. These studies suggest a tissue-dependent role of CDX2 in carcinogenesis and indicate that possible involvement of CDX2 needs to be determined for each tumour type individually.

Tumours of the anterior pituitary lobe account for approximately 7.5 percent of all intracranial tumours with a reported annual incidence of 8.2-14.7 per 100 000 population [4]. The prevalence increases with age and shows a female predominance which has been attributed to the expression of sex steroid receptors by some authors [33]. While a significant correlation exists between proliferative activity and tumour invasiveness [14,19] a correlation with tumour recurrence has not been established. The current WHO classification lists pituitary adenomas with an "elevated" mitotic index and a MIB-1 labelling index greater than 3% as "atypical adenomas" [18], while pituitary carcinomas are exceptionally rare neoplasms.

Craniopharyngiomas are epithelial tumours that are assumed to arise from a neoplastic transformation of ectodermal-derived Rathke's pouch cell remnants [25]. The tumours have bimodal peak incidences. While adamantinous craniopharyngiomas are seen in children and adults, the papillary subtype is almost restricted to adults [3]. Although slowly-growing benign neoplasms, they tend to infiltrate adjacent bone and brain structures and surgical resection might be a challenge [28]. The rate of recurrence is dependant on the radicality of tumour resection on the one hand, but on the other hand the p53 protein expression in the tumour plays a significant role [32].

Since CDX2 is expressed in normal neuroendocrine cells of the intestine and gastric fundus [2] as well as in many carcinoid tumours [6,22], and since genome-wide mRNA analysis revealed elevated expression levels for CDX2 in normal pituitary tissue that were above leukaemic cell lines [30], we hypothesized that CDX2 might play a role in the tumourigenesis of pituitary adenomas. Additionally, we examined adamantinous and papillary craniopharyngiomas since CDX2

expression has been recently reported in squamous epithelia [13,35,36], but to date craniopharyngiomas have not been examined for a possible CDX2 expression.

Material and methods

We examined paraffin-embedded samples from normal pituitary gland ($n = 28$), pituitary adenomas ($n = 75$) and craniopharyngiomas ($n = 23$) by immunohistochemistry.

Normal pituitary tissue (11 male, 17 female; age 13-86 yrs, mean 55.6 yrs) was taken from routine autopsy brains ($n = 21$) and from neurosurgical specimen ($n = 7$) which contained normal pituitary tissue coincidentally. In the latter, surgery had been performed for Rathke's cleft cysts or hypophysitis. From the autopsy samples two probes (1.0 mm in diameter, one centrally and one laterally) were taken from the anterior lobe (pars distalis) and aligned on a tissue micro array using a conventional tissue microarrayer (Beecher Instruments, Sun Prairie, Wisconsin, USA). For surgical cases the whole slides were analyzed.

Of the pituitary adenomas (39 male, 38 female; age 19-79 yrs, mean 51.3 yrs), seven were classified as atypical pituitary adenoma, 7 showed the aspect of obvious invasive growth in imaging studies according to grade 3 or 4 of parasellar growth [17], 11 were recurrent tumours (up to 10 years after first operation). 34 were hormonally silent (null-cell-adenomas), 20 expressed growth hormone, 7 were corticotrophs, 9 were prolactinomas, 3 were mixed tumours, 1 FSHoma and 1 TSHoma.

The craniopharyngiomas were in 17 cases adamantinous (6 female, 11 male, age 4-74 yrs, mean 36.7) and in 6 papillary (3 female, 3 male, age 33-49, mean 41.8 yrs). Two representative probes (1.0 mm in diameter) were taken from each tumour and aligned on a tissue micro array.

Samples were immunostained using a monoclonal mouse IgG1 antibody directed against the full length human CDX2 protein (Zytomed Systems, Berlin, Germany; clone CDX2-88, dilution 1:25) using an automated immunohistochemistry staining system (BenchMark®, Ventana Medical Systems, Tucson, Arizona, USA). The protocol (extended cell conditioning pretreatment for 30 min) is based on an indirect biotin-avidin system and uses a universal biotinylated immunoglobulin secondary antibody and diaminobenzidine substrate as chromogen. Sections were finally

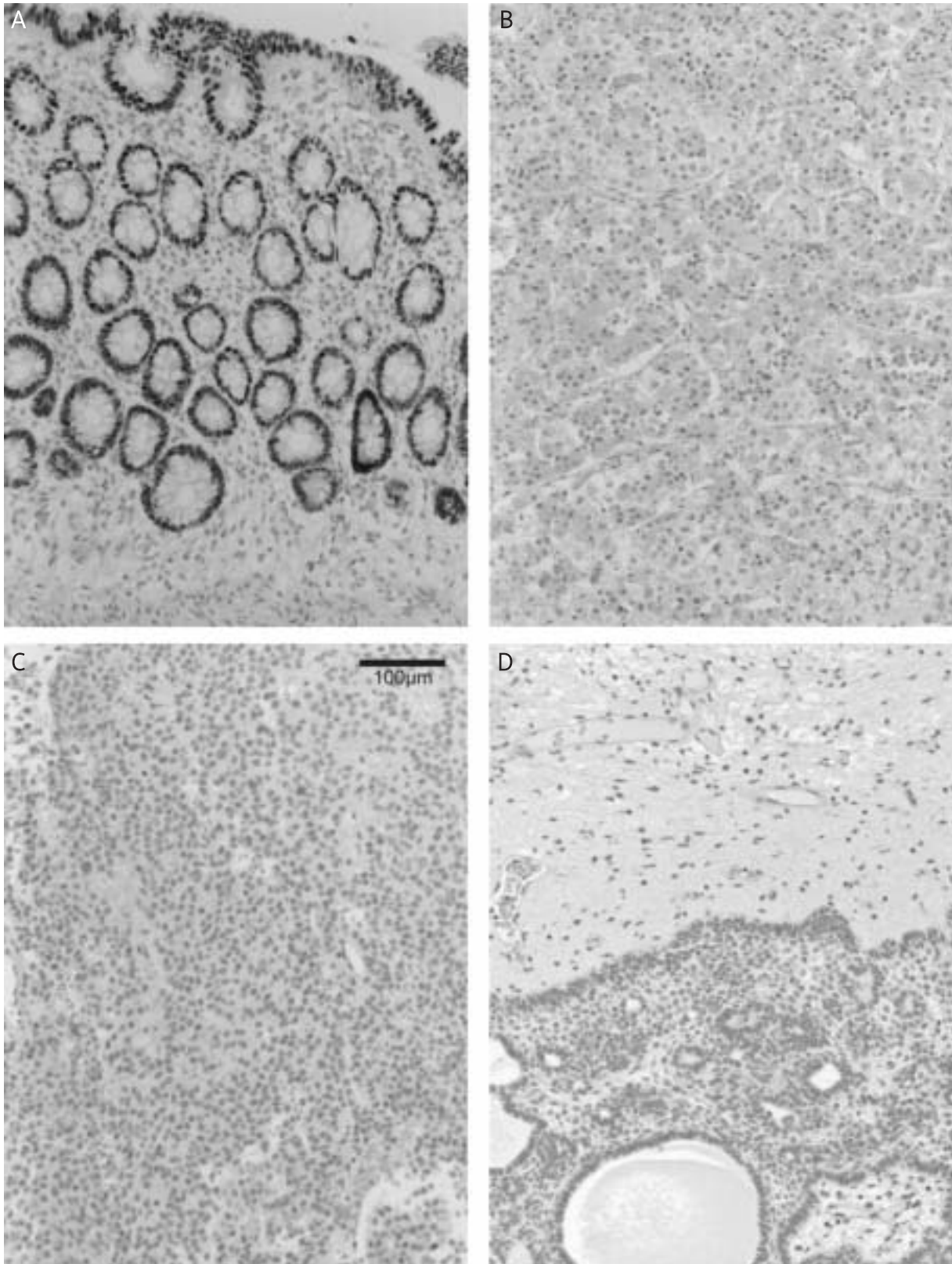


Fig. 1. Positive control shows a distinct nuclear expression of CDX2 in normal colorectal mucosa (A). Normal adenohypophysis (B), a pituitary adenoma (C) and an adamantinous craniopharyngioma (D) lacking immunoreactivity for CDX2.

counterstained with haematoxylin. In negative controls, the primary antibody was omitted. Normal human colon tissue served as positive control (Fig. 1A). This study was carried out according to the guidelines of the University's ethics commission.

Results

CDX2 expression in normal adenohypophysis

All autopsy cases and surgical specimen examined lacked expression of CDX2 in the nuclei of epithelium, connective tissue stroma or blood vessels (Fig. 1B). Furthermore, CDX2 expression was also absent in neighbouring brain tissue, including ependymal cells and cyst epithelium (wall of Rathke's cleft cysts).

CDX2 expression in pituitary adenomas and craniopharyngiomas

No nuclear CDX2 immunostaining was found in any of the pituitary adenomas, neither in classical adenomas (Fig. 1C) nor in atypical, invasive or recurrent adenomas.

Likewise, all adamantinous (Fig. 1D) and papillary craniopharyngiomas were immunonegative for CDX2.

Discussion

CDX2 is a nuclear transcription factor and commercially available antibodies are widely used to characterize colorectal adenocarcinomas [37]. However, CDX2 is not specific to intestinal epithelium. Large studies have shown that CDX2 is also expressed in various other epithelial neoplasms, including tumours of ovaries, prostate, breast, lung and uterus [2,22,37], but these studies did not include pituitary adenomas. Moskaluk *et al.* reported an absence of CDX2 in normal pituitary tissue, but did not give detailed particulars on the number of samples that he examined [22]. A study by Erickson *et al.* reporting CDX2 expression in neuroendocrine tumours also included 12 pituitary adenomas but did not specify the hormonal activity of these tumours [6].

Therefore, we included in our series samples from normal pituitary gland and pituitary adenomas putting emphasis on different hormonal expression as well as hormonally silent tumours (including recurrent and atypical adenomas). In all cases investigated normal and neoplastic adenohypophyseal

tissue lacked expression of CDX2, indicating that CDX2 is not involved in differentiation of the anterior pituitary or in tumorigenesis of pituitary adenomas. Likewise, neuroendocrine tumours of parathyroid, paragangliomas and pheochromocytomas have been previously reported to be immunonegative for CDX2 [6].

Metastases to the pituitary are not uncommon [7,12,20,26,31] and need to be distinguished from primary pituitary tumours. The incidence of intracranial metastases of colorectal tumours varies in the literature from 2-16% of all carcinomas [29,31]. Strickland-Marmol and colleagues reported for CDX2 a specificity of 100%, and 83% sensitivity to determine gastrointestinal adenocarcinomas metastatic to the brain. Thus, the now confirmed negative immunoreactivity of pituitary adenomas for CDX2 might be useful for diagnostic purposes, especially in cases of metastatic neuroendocrine tumours, which also express synaptophysin, but in contrast to pituitary adenomas are known to express CDX2 [6].

An aberrant CDX2 expression has also been reported in epithelial lesions with squamous differentiation [13,35,36]. Interestingly, CDX2 expression is epigenetically silenced in squamous oesophageal cancer [8]. To our best knowledge, CDX2 expression in craniopharyngiomas has not been previously examined. The current work shows that the squamous tumour cells in craniopharyngiomas are constantly negative for CDX2.

In summary, we demonstrate that CDX2 is absent in normal pituitary gland as well as in pituitary adenomas and craniopharyngiomas. Thus, CDX2 may be helpful to distinguish metastatic carcinomas affecting the sellar region from primary pituitary tumours.

References

1. Bakarlis S, Cetinkaya A, Ezberci F, Ekerbicer H. Expression of homeodomain protein CDX2 in colorectal adenoma and adenocarcinoma. *Histol Histopathol* 2008; 23: 1043-1047.
2. Barbareschi M, Roldo C, Zamboni G, Capelli P, Cavazza A, Macri E, Cangi MG, Chilosi M, Doglioni C. CDX-2 homeobox gene product expression in neuroendocrine tumors: its role as a marker of intestinal neuroendocrine tumors. *Am J Surg Pathol* 2004; 28: 1169-1176.
3. Bunin GR, Surawicz TS, Witman PA, Preston-Martin S, Davis F, Bruner JM. The descriptive epidemiology of craniopharyngioma. *J Neurosurg* 1998; 89: 547-551.
4. Central Brain Tumor Register of the United States. 2007-2008 statistical report. Available at <http://www.cbtrus.org/reports/2007-2008/2007report.pdf> (last accessed 9th September 2009).

5. Chawengsaksophak K, James R, Hammond VE, Köntgen F, Beck F. Homeosis and intestinal tumours in Cdx2 mutant mice. *Nature* 1997; 386: 84-87.
6. Erickson LA, Papouchado B, Dimashkieh H, Zhang S, Nakamura N, Lloyd RV. Cdx2 as a marker for neuroendocrine tumors of unknown primary sites. *Endocr Pathol* 2004; 15: 247-252.
7. Fassett DR, Couldwell WT. Metastases to the pituitary gland. *Neurosurg Focus* 2004; 16: E8, pp. 1-4.
8. Guo M, House MG, Suzuki H, Ye Y, Brock MV, Lu F, Liu Z, Rustgi AK, Herman JG. Epigenetic silencing of CDX2 is a feature of squamous esophageal cancer. *Int J Cancer* 2007; 121: 1219-1226.
9. Guo RJ, Suh ER, Lynch JP. The role of Cdx proteins in intestinal development and cancer. *Cancer Biol Ther* 2004; 3: 593-601.
10. Heckman CA, Mehew JW, Ying GG, Introna M, Golay J, Boxer LM. A-Myb up-regulates Bcl-2 through a Cdx binding site in t(14; 18) lymphoma cells. *J Biol Chem* 2000; 275: 6499-6508.
11. Herawi M, De Marzo AM, Kristiansen G, Epstein JI. Expression of CDX2 in benign tissue and adenocarcinoma of the prostate. *Hum Pathol* 2007; 38: 72-78.
12. Heshmati HM, Scheithauer BW, Young WF. Metastases to the pituitary gland. *Endocrinologist* 2002; 12: 45-49.
13. Houghton O, Connolly LE, McCluggage WG. Morules in endometrioid proliferations of the uterus and ovary consistently express the intestinal transcription factor CDX2. *Histopathol* 2008; 53: 156-165.
14. Jaffrain-Rea ML, Di Stefano D, Minniti G, Esposito V, Bultrini A, Ferretti E, Santoro A, Faticanti Scucchi L, Gulino A, Cantore G. A critical reappraisal of MIB-1 labelling index significance in a large series of pituitary tumours: secreting versus non-secreting adenomas. *Endocr Relat Cancer* 2002; 9: 103-113.
15. Jin T, Li H. Pou homeodomain protein OCT1 is implicated in the expression of the caudal-related homeobox gene Cdx-2. *J Biol Chem* 2001; 276: 14752-14758.
16. Kim S, Domon-Dell C, Wang Q, Chung DH, Di Cristofano A, Pandolfi PP, Freund JN, Evers BM. PTEN and TNF-alpha regulation of the intestinal-specific Cdx-2 homeobox gene through a PI3K, PKB/Akt, and NF-kappaB-dependent pathway. *Gastroenterol* 2002; 123: 1163-1178.
17. Knosp E, Steiner E, Kitz K, Matula C. Pituitary Adenomas with Invasion of the Cavernous Sinus Space: A Magnetic Resonance Imaging Classification Compared with Surgical Findings. *Neurosurg* 1993; 33: 610-618.
18. Lloyd RV, Kovacs K, Young WF, Farrell WE, Asa SL. Tumors of the pituitary gland. In: DeLellis RA, Lloyd RV, Heitz PU, Eng C (eds.). *Pathology & Genetics. WHO classification. Tumours of endocrine organs.* IARC Press, Lyon 2004; p. 10-37.
19. Losa M, Franzin A, Mangili F, Terreni MR, Barzaghi R, Veglia F, Mortini P, Giovanelli M. Proliferation index of nonfunctioning pituitary adenomas: correlations with clinical characteristics and long-term follow-up results. *Neurosurg* 2000; 47: 1313-1318.
20. Max MB, Deck DF, Rottenberg DA. Pituitary metastasis: incidence in cancer patients and clinical differentiation from pituitary adenoma. *Neurology* 1981; 31: 998-1002.
21. Mazziotta RM, Borczuk AC, Powell CA, Mansukhani M. CDX2 immunostaining as a gastrointestinal marker: expression in lung carcinomas is a potential pitfall. *Appl Immunohistochem Mol Morphol* 2005; 13: 55-60.
22. Moskaluk CA, Zhang H, Powell SM, Cerilli LA, Hampton GM, Frierson HF Jr. Cdx2 protein expression in normal and malignant human tissues: an immuno-histochemical survey using tissue microarrays. *Mod Pathol* 2003; 16: 913-919.
23. Onofre AS, Pomjanski N, Buckstegge B, Böcking A. Immunocytochemical diagnosis of hepatocellular carcinoma and identification of carcinomas of unknown primary metastatic to the liver on fine-needle aspiration cytologies. *Cancer* 2007; 111: 259-268.
24. Riedt T, Ebinger M, Salih HR, Tomiuk J, Handgretinger R, Kanz L, Grunebach F, Lengerke C. Aberrant expression of the homeobox gene CDX2 in pediatric acute lymphoblastic leukemia. *Blood (Epub 2009 Feb 13).*
25. Rushing EJ, Giangaspero F, Paulus W, Burger PC. Craniopharyngioma. In: *Pathology & Genetics. WHO classification of tumours of the central nervous system.* IARC Press, Lyon 2007; pp. 238-240.
26. Saeger W, Riedel M, Schröder H. Metastasen in der Hypophyse und Sella. *Pathologe* 1985; 6: 308-312.
27. Scholl C, Bansal D, Döhner K, Eiwien K, Huntly BJ, Lee BH, Rücker FG, Schlenk RF, Bullinger L, Döhner H, Gilliland DG, Fröhling S. The homeobox gene CDX2 is aberrantly expressed in most cases of acute myeloid leukemia and promotes leukemogenesis. *J Clin Invest* 2007; 117: 1037-1048.
28. Shi XE, Wu B, Fan T, Zhou ZQ, Zhang YL. Craniopharyngioma: surgical experience of 309 cases in China. *Clin Neurol Neurosurg* 2008; 110: 151-159.
29. Strickland-Marmol LB, Khoo A, Livingston SK, Rojiani A. Utility of tissue-specific transcription factors thyroid transcription factor 1 and Cdx2 in determining the primary site of metastatic adenocarcinomas to the brain. *Arch Pathol Lab Med* 2007; 131: 1686-1690.
30. Su AI, Wiltshire T, Batalov S, Lapp H, Ching KA, Block D, Zhang J, Soden R, Hayakawa M, Kreiman G, Cooke MP, Walker JR, Hogenesch JB. A gene atlas of the mouse and human protein encoding transcriptomes. *Proc Natl Acad Sci USA* 2004; 101: 6062-6067.
31. Teears R, Silverman EM. Clinicopathologic review of 88 cases of carcinoma metastatic to the pituitary gland. *Cancer* 1975; 36: 216-220.
32. Tena-Suck ML, Salinas-Lara C, Arce-Arellano RI, Rembao-Bojórquez D, Morales-Espinosa D, Sotelo J, Arrieta O. Clinicopathological and immunohistochemical characteristics associated to recurrence/regrowth of craniopharyngiomas. *Clin Neurol Neurosurg* 2006; 108: 661-669.
33. Thapar K, Kovacs K, Stefanescu L, Scheithauer B, Killinger DW, Lloyd RV, Smyth HS, Barr A, Thorner MO, Gaylinn B, Laws ER Jr. Overexpression of the growth-hormone-releasing hormone gene in acromegaly-associated pituitary tumors. An event associated with neoplastic progression and aggressive behavior. *Am J Pathol* 1997; 151: 769-784.
34. Thoene S, Rawat VP, Heilmeyer B, Hoster E, Metzeler KH, Herold T, Hiddemann W, Gökbüget N, Hoelzer D, Bohlander SK, Feuring-Buske M, Buske C. The homeobox gene CDX2 is aberrantly expressed and associated with an inferior prognosis in patients with acute lymphoblastic leukemia. *Leukemia (Epub 2009 Jan 22).*
35. Wani Y, Notohara K, Fujisawa M. Aberrant expression of an "intestinal marker" Cdx2 in pyloric gland adenoma of the gallbladder. *Virchows Arch* 2008; 453: 521-527.

36. Wani Y, Notohara K, Saegusa M, Tsukayama C. Aberrant Cdx2 expression in endometrial lesions with squamous differentiation: important role of Cdx2 in squamous morula formation. *Hum Pathol* 2008; 39: 1072-1079.
37. Werling RW, Yaziji H, Bacchi CE, Gown AM. CDX2, a highly sensitive and specific marker of adenocarcinomas of intestinal origin: an immunohistochemical survey of 476 primary and metastatic carcinomas. *Am J Surg Pathol* 2003; 27: 303-310.